

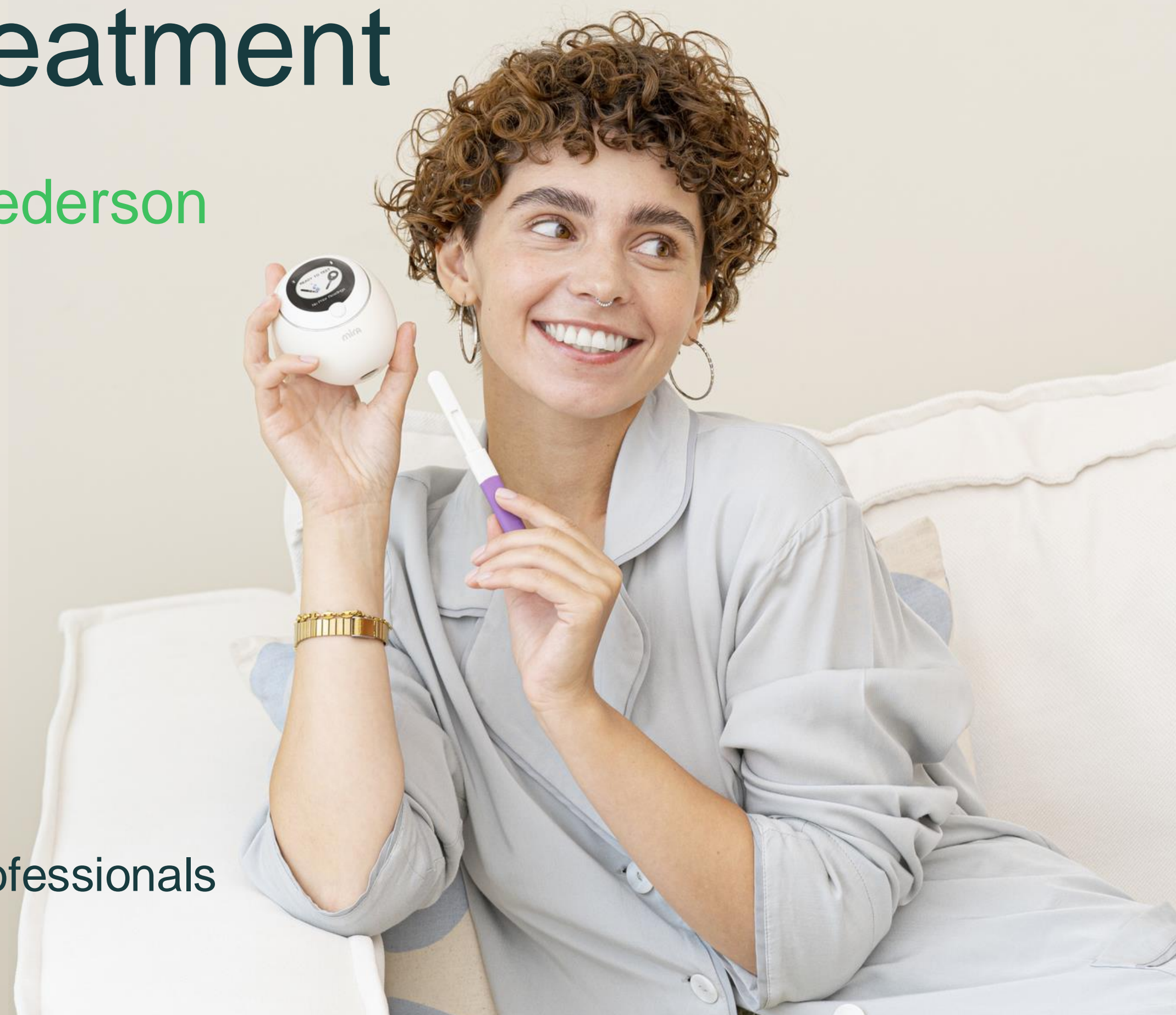How Mira assists in clinical evaluation and treatment

Case Reports with Dr. Sarah Pederson

Vera
HEALTH & FERTILITY



For Healthcare Professionals



Patient background

Patient is a 28yo G0 who presents with severe menstrual cramps

Past medical history: None

Past surgical history: None

Medications: None

BMI: 32

Diet: Tries to eat healthy, no food restrictions

Exercise: 3–4 days of workouts- biking, weights, daily walks, weekend biking



Patient situation

Patient is a 28yo G0 who presents with severe menstrual cramps

She was on OCPs for 6 years, after coming off of OCPs had irregular cycles for 2 years

Had an episode of severe abdominal pain, went to the ER, was diagnosed with a ruptured ovarian cyst. She continued to have sharp pains around menses and ovulation

Follow up ultrasound showed a complex left ovarian cyst measuring $7.8 \times 4.9 \times 4.9$ cm. She tried 2 cycles of progesterone but the cyst continued to grow. It was recommended that she undergo surgical management.

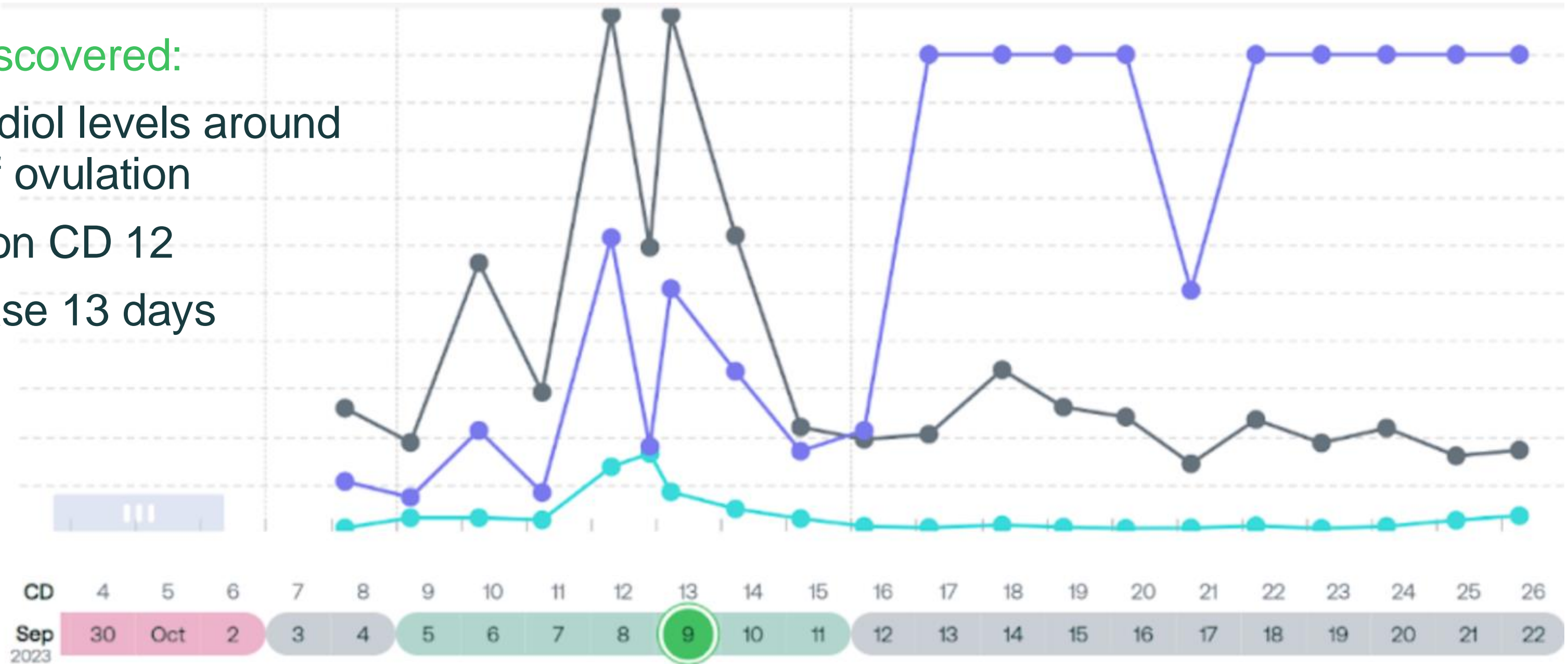
She recently got married and wants to try to conceive. She started using Mira to make sure her hormones were balanced postoperatively



Initial Mira Chart

Mira data discovered:

- High estradiol levels around the time of ovulation
- LH surge on CD 12
- Luteal phase 13 days



Patient is taking post peak progesterone after surgery



Labs / Imaging or other results

US report shows left ovarian cyst 7.8 × 4.9 × 4.9 cm, complex cyst

CD3 Labs:

Prolactin slightly elevated at 25

Estradiol 30

LH 4.2

FSH 5.3

TPO antibodies normal

Thyroglobulin antibodies elevated 5.8

TSH 2.14

DHEAS normal

Gut health test: mild dysbiosis

Vaginitis: Positive for bacterial vaginosis



Treatment / Interventions / Assistance

Patient underwent operative hysteroscopy and robotic assisted bilateral ovarian cystectomy and excision of endometriosis. Pathology consistent with endometriosis. Chromopertubation with bilateral fill and spill noted.

Postoperatively, she was placed on an anti-inflammatory diet for endometriosis and gluten free, dairy free diet for diagnosis of Hashimotos.

She was also started on post peak progesterone for 3 cycles and Omega 3 to prevent endometriosis regrowth. She was started on IgG and a probiotic for her gut health.

She was given a course of metronidazole and clindamycin to treat refractory bacterial vaginosis.

She was also started on Vitex supplement for elevated prolactin.



Labs / Imaging or other results

CD3

AMH 2.18

Thyroid antibodies neg after GF, DF diet

Progesterone 2.1

Prolactin 9.4 normal

Estradiol 43

FSH 6.3

LH 2.6

TSH 2.5

HgbA1C 5.3

Post peak

FSH 2

LH 1.7

Progesterone 11

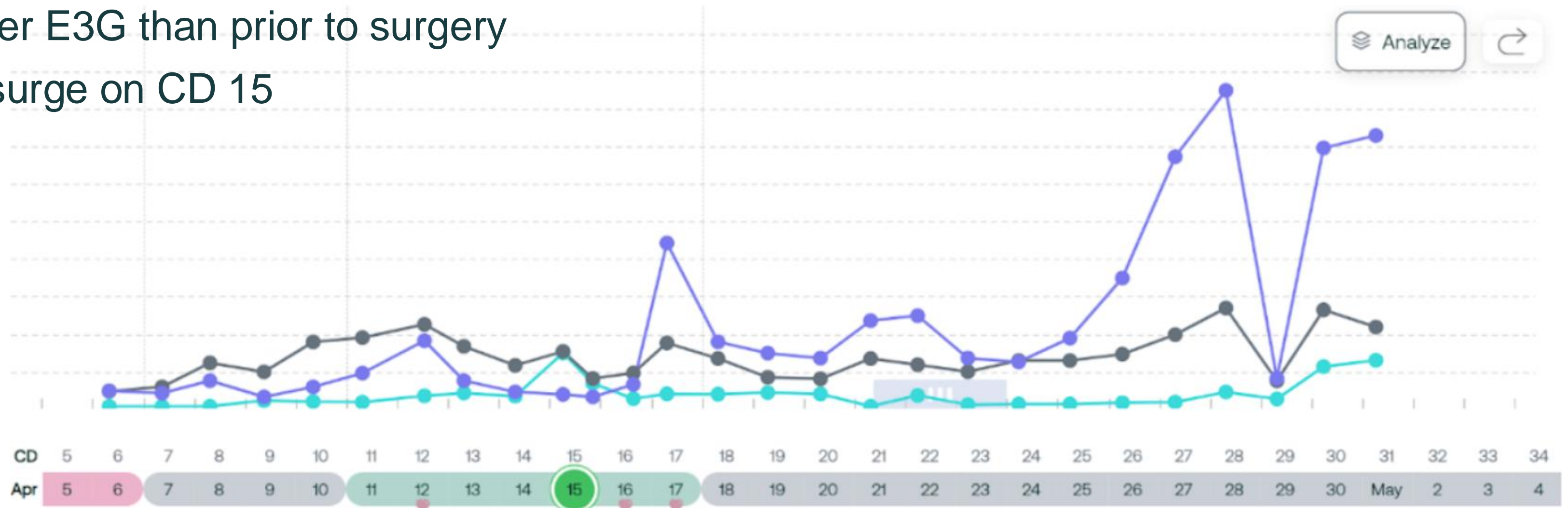
Estradiol 196



Follow Up Mira Data: Conception Cycle

Mira data discovered:

- Lower E3G than prior to surgery
- LH surge on CD 15



Summary

SK was a 28 yo G0 who presented with painful menses. An ultrasound showed a complex 8 cm ovarian cyst. She underwent surgical management with excision of the cyst which turned out to be an endometrioma, and excision of endometriosis which was confirmed on pathology.

Part of her workup included labs, gut health testing, and vaginitis testing. She was also found to have Hashimoto's thyroiditis and bacterial vaginosis. Her Mira data and labs showed evidence of estrogen dominance.

She was started on an anti-inflammatory diet, Omega 3, and post peak progesterone for the endometriosis. She was also gluten and dairy free to help with inflammation from Hashimotos. She was treated with 2 rounds of antibiotics for bacterial vaginosis and started on Vitex which normalized her prolactin levels. Her estradiol on Mira after these interventions was much lower.

She conceived the month she started trying!



Thank you!